



# Nonencephalopathic Psychiatric Manifestations (NEPM) and Response to Niacin in Pellagra: A Scoping Review

Roshan Sutar<sup>1\*</sup>, Devendra S. Basera<sup>1</sup>, Ashish Pakhre<sup>1</sup>, Pooja Chaudhary<sup>1</sup>, Anuja Lahiri<sup>2</sup>.

<sup>1</sup>Department of Psychiatry, All India Institute of Medical Sciences, Bhopal, Madhya Pradesh, India

<sup>2</sup>Department of Community and Family Medicine, All India Institute of Medical Sciences, Bhopal, Madhya Pradesh, India

## ARTICLE INFO

### \*Correspondence:

Roshan Sutar

roshidoc@yahoo.co.in

Department of Psychiatry,  
All India Institute of  
Medical Sciences (AIIMS),  
Bhopal, Madhya Pradesh,  
India

### Dates:

Received: 22-08-2022

Accepted: 27-09-2022

Published: 05-11-2022

### Keywords:

Kynurenine, Niacin,  
Pellagra, Psychiatric  
manifestations,  
Serotonin, Tryptophan

### How to Cite:

Sutar R, Basera DS,  
Pakhre A, Chaudhary  
P, Lahiri A. Nonenceph-  
alopathic Psychiatric  
Manifestation (NEPM)  
and Response to Niacin  
in Pellagra: A Scoping  
Review. *Indian Journal  
of Behavioural Sciences.*  
2022;25(2):128-142.  
doi: 10.55229/ijbs.v25i2.08

## Abstract

Psychiatric manifestations of pellagra could be subtle but important to recognize in clinical practice. These may vary from non-syndromic symptoms of anxiety, depression, and psychosis to pellagrous encephalopathy. The course and outcome of pellagra's non-encephalopathic psychiatric manifestations (NEPM) are variable and have not received much attention. Therefore, a review in this regard is deemed necessary to understand the evolution of psychiatric symptoms and possible neurochemical changes produced in pellagra. A focused scoping review of the literature using Preferred Reporting Items for Systematic reviews and Meta-Analyses- extension for Scoping Reviews (PRISMA-ScR) guidelines was carried out to chart the results of studies to find out the characteristic nature of NEPM, role of niacin, and underlying etiopathogenesis. The review included 12 studies comprising 271 participants. Depressive and insomnia symptoms were the most frequent manifestations of NEPM followed by anxiety, thought disorder, psychomotor agitation, hallucinations, confusion, and disorientation. Alcohol use remains the most common cause of NEPM in pellagra, followed by nutritional deficiency. The alteration in the kynurenine pathway is a probable mechanism implicated in the NEPM of pellagra and future research should explore the role of niacin replacement in such patients. The findings of the review incite further discussion and research on biomarkers for patients with pellagra and subtype of patients with depression who share a common immune-inflammatory pathway.

## INTRODUCTION

Psychiatric manifestations of pellagra are mostly described in the context of acute symptoms of delirium or encephalopathy. Besides these neuro-psychiatric conditions, non-specific psychiatric symptoms such as irritability, tiredness, fatigue, restlessness, depression, and apathy during pellagra are commonly encountered but under-recognized and under-treated in clinical practice.<sup>1</sup> Even before the development of encephalopathy or delirium, subacute depressive or psychotic symptoms have been reported during pellagra.<sup>2</sup> Among various factors that can cause niacin deficiency, chronic alcohol consumption is an important one.<sup>3-8</sup> The other risk factors may include nutritional deficiency, predisposing dietary pattern (predominant maize or jowar as staple food), food faddism, malabsorption syndrome, and treatment with isoniazid. Although many of these factors have been taken care of by the process of food

fortification and endorsing the benefits of consuming a balanced diet, pellagra continues to exist in the developing world. The classical triad of pellagra is described as the presence of diarrhea, dermatitis, and dementia. However, in contemporary medicine, it is rare to see the progressive chronic course of pellagra leading to dementia.<sup>7</sup> As the prevalence of classical pellagra has reduced over time, the presentation of neuropsychiatric manifestations perhaps has become subtle and commonly found among people with alcohol use disorder. These psychiatric symptoms may present at the subsyndromal level and are often missed in clinical practice, thus require a high level of clinical suspicion in routine practice.

Further, depressive symptoms in pellagra may not be associated with any of the classical pellagrous manifestations, including gastrointestinal, dermatological (*pellagra sine pellagra*), or dementia-like syndrome.<sup>7</sup> Furthermore, identifying and screening such clinical presentations require the exploration of underlying biochemical pathways to identify biomarkers. Studies conducted earlier have missed the etiopathogenesis perspective due to the overt focus on the management of delirium or encephalopathy associated with alcohol in mental health care settings.<sup>9</sup> Therefore, we defined these subsyndromal psychiatric symptoms in pellagra as non-encephalopathic psychiatric manifestations (NEPM), and conducted a scoping review of the literature to find their association with alcohol consumption, niacin supplementation, and underlying biochemical pathways.

## MATERIAL AND METHODS

A literature review on pellagra and NEPM was conducted using PRISMA-ScR guidelines.<sup>10</sup>

**Objective:** The review objectives were to determine the magnitude of psychiatric manifestations in pellagra, the response to niacin and to review the literature on underlying etiopathogenesis in this context.

### Eligibility Criteria

**Type of Studies** We included all types of original research studies published till May 2021 including case reports, case series, and comparative studies

which focused on psychiatric manifestations of pellagra, including syndromic or non-syndromic symptoms of depression, anxiety, and psychosis. We excluded the reviews, meta-analyses, and studies primarily focussing on encephalopathy. Studies containing only gastrointestinal symptoms such as diarrhea, and constipation, etc., or only neurological symptoms such as seizure, neuropathy, etc., or only dermatological symptoms of pellagra were excluded.

**Type of Interventions** We included studies focusing on dietary supplementation, medical treatment, combined supplementation, or replacement with niacin, group-B vitamins, or both to treat or reverse the psychiatric manifestations of pellagra, irrespective of the concomitant treatment with other psychotropics.

**Type of participants** We included studies with participants of any age and gender who had been reported to have psychiatric manifestations of pellagra exclusively (*pellagra sine pellagra*) or psychiatric manifestations along with dermatological and gastrointestinal manifestations of any type and any severity, admitted, out-patient, or under community treatment. We included all the studies with any underlying cause leading to the development of pellagra.

**Search Strategy** A systematic literature search of the following databases was conducted on 15<sup>th</sup> May 2021 by two independent authors (RS and PC): Cochrane, PubMed, and Google scholar. In addition, the reference lists of the pertinent literature were screened for the relevant studies.

**Search keywords:** The literature was searched using keywords: “pellagra” AND “mental illness”, “niacin” AND “mental illness”, “pellagra” AND “psychosis”, “pellagra” AND “psychiatric disorder”, “pellagra” AND “depression”, “pellagra” AND “anxiety”, “pellagra” AND “depression” OR “alcohol” OR “anxiety” OR “psychosis”, OR “neuropsychiatric”

**Data Collection and Analysis** The outcome variables used for data extraction constituted author name, year of publication, study design, country of research, age (mean or median), sample size, psychiatric manifestations of pellagra, systemic manifestations (gastrointestinal, neurological, and dermatological) of pellagra, supplementation with

niacin, and other vitamins, the details of psychotropic medications, and radiological or pathological findings of the associated lesions in pellagra.

### Data Extraction and Management

Three authors (PC, RS, and DB) independently extracted data from the selected studies using a standardized coding form prepared in Microsoft Excel 2010. They discussed any differences in the data extraction till the resolution of conflict by a third author (AP). The following data were extracted:

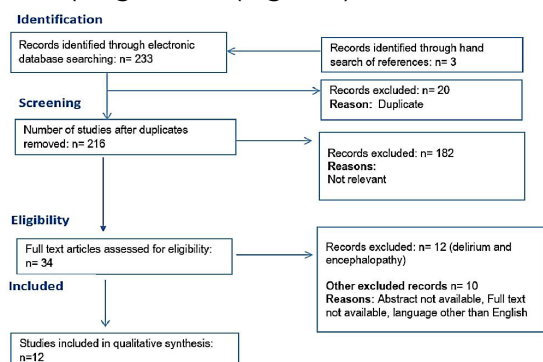
### Synthesis of Results

The results of the study were tabulated to mention the characteristic findings of each study describing causes of pellagra, symptoms of NEPM, and etiopathogenesis of NEPM. A schematic charting method was used to display the results of the synthesis. The studies and reports predominantly describing delirium and encephalopathy in the context of pellagra were identified and described separately.

## RESULTS

### Selection of Sources of Evidence

We identified 236 relevant studies on psychiatric manifestations of pellagra, of which 20 were removed because of duplicates, 216 were screened for relevancy and 182 were excluded as they were not meeting the review objective. The full text and abstract of the few studies were unavailable, while 12 studies were on encephalopathic psychiatric manifestations (EPM), hence described separately. Finally, 12 studies with 271 participants were included in the scoping review (Figure 1).



**Figure 1:** Flowchart of the selection of sources of evidence

### Characteristics of Sources of Evidence

Among included studies, four studies used case-control design and all of them were from India, whereas seven were case reports from Japan, Greece, the USA, India, Brazil, China, and Canada, and a case series from Japan. Case-control studies from India reported places near Hyderabad in Telangana and Udaipur in Rajasthan, where maize or jowar (*Sorghum vulgare*) constitutes the major staple diet.

### Critical Appraisal within Sources of Evidence

The case-control studies from India had a less robust methodology; three were conducted before 1975. All the case-control studies predominantly utilized the purposive sampling technique for the comparison of dietary patterns leading to the development of pellagra. All the included case reports and case series followed the Committee on Publication Ethics (COPE) guidelines for reporting their findings.

### Results of Individual Sources of Evidence

Nine studies mentioned the co-occurrence of depressive symptoms in pellagra, including two case-control studies, six case reports, and one case series (Table 1).

The participant's age at the time of the presentation ranged from 25–51 years. The most common precipitating factors for pellagra were alcohol consumption in five studies,<sup>11-15</sup> dietary pattern in four studies<sup>16-18</sup> nutritional deficiency in two studies,<sup>2,19</sup> and isoniazid therapy in one case series.<sup>20</sup> The NEPM described in pellagrins included depressed mood, apathy, irritable mood, reduced speech tempo, easy fatigability, psychomotor retardation, psychomotor agitation, dysphoria, and loss of appetite. None of the reports used objective assessment tools for the assessments except one study, which used symptom checklist-90 revised -SCL-90.<sup>16</sup> Most of the cases were presented to an emergency department. Other associated symptoms included anxiety, nervousness, insomnia, confusion, delirium, hallucination, and delusion. Two cases had delusion as the only psychotic symptoms.<sup>12,13</sup> While three case reports mentioned visual and auditory hallucinations with or without delusions.<sup>11,19,20</sup> None of the case reports differentiated the course of depressive

**Table 1:** Non-encephalopathic psychiatric manifestations (NEPM) of pellagra

S. no	Author and year	Type of study	Region	Sample size	Mean age (years)	Probable etiology of pellagra	Psychiatric manifestations	Associated dermatological and gastrointestinal manifestations	The characteristic finding of the study
1	Krishnaswamy and Murthy, 1970	Case-control study	Hyderabad, India	16 cases and 10 controls	Not specified	Dietary (millet jowar: Sorghum Vulgare)	Depression, insomnia, fatigue, and apprehension.	Bilateral, symmetrical dermatitis, angular stomatitis, glossitis, and nasolabial dyssebacea	Platelet serotonin was significantly lower in pellagrins with mental changes as compared to those without mental changes
2	Krishnaswamy, 1971	Case-control study	Hyderabad, India	11 cases and 10 healthy controls	Not specified	Dietary deficiency of niacin	Depression, anxiety, apprehension, and insomnia	Typical bilateral and symmetrical dermatitis	Evaluation and comparison of basal cortisol levels and response to ACTH administration.  Basal cortisol and ACTH response in the two groups were comparable.
3	Raghuram and Krishnaswamy, 1975	Case-control study	Hyderabad, India	13	25-45 (Range)	Dietary deficiency of niacin	Depression, apathy, and insomnia.	Bilateral symmetrical dermatitis, diarrhea	Blood, CSF, and Urine samples were used for measuring 5HT and 5HIAA at baseline and after Tryptophan therapy. Insomnia responded within 48 to 72 hours of therapy.  The abnormal mental status of pellagrins was associated with low serotonin levels in platelets, and reduced 5-HIAA concentrations in urine and CSF.  There was no correlation among 5-HT in platelets, 5-HIAA in CSF, and the severity of the mental status.

4	Ishii and Nishihara, 1985	case reports	Japan	8	51	Isoniazid therapy for tuberculosis	Depression, insomnia, anxiety, restlessness, auditory and visual hallucinations, and delirium	Typical Symmetrical pellagra dermatitis on the exposed parts of the body. skin pigmentation, facial lesions were described as dyssebacia and eczema-like dermatitis with rough and scaly lesions	Necropsy findings in eight cases were carried out of which four cases had no dermatological findings which prove that pellagra encephalopathy could exist without skin lesions (pellagra sine pellagra)
5	Pitsavas <i>et al.</i> , 2004	Case report	Greece	1	44, male	Alcohol	Psychomotor agitation, anxiety, nervousness, irritability, insomnia, persecutory delusional ideas, complex visual hallucinations, and zoopsia,	Hyperkeratotic, exfoliative, and pruritic Rash on extremities	Supplemented with multiple vitamin preparations, including 500 mg nicotinic acid, for five days. Within the first day, the patient regained consciousness. The visual hallucinations. delusional ideas of persecution and mild hypertension were resolved after a week of treatment.
6	Delgado-Sanchez <i>et al.</i> , 2008	Case report	USA	1	42, male	Alcohol	Confusion and thought disorder	Rash on the sun-exposed parts of the body; erythematous to scaly pattern with marked skin dryness	Niacin was supplemented at a dosage of 150 mg/day. Rapid response to niacin was noted within a week. Blood tryptophan levels were in the lower range (14 mmol/L; reference range, 20–95 mmol/L).
7	Prakash <i>et al.</i> , 2008a	Case report	Ranchi, India	1	45, male	Alcohol	Apathy, psychomotor retardation, slow and soft quality of speech, dysphoric affect, a delusion of parasitosis, and poor insight.	Diarrhea, Casal necklace scaly lesions on his skin in the sun-exposed parts, most prominent being on the dorsum of his both hands, both feet, forehead and below the neck	Oral haloperidol 15–20 mg/day and niacin 50 mg/day were supplemented in q. i. doses. Within 4 days, delusion disappeared and the patient developed dysphoria and ideas of hopelessness and helplessness.

8	Luthe and Sato, 2017	Case report	Japan	1	37, male	Alcohol	Agitation, loss of appetite, and disorientation.	Diarrhea, bilateral erythematous, and erosive skin changes over angles of mouth with burning and itching.	Supplemented with nicotinic acid up to 150 mg/d, Within two days, the patient became alert and oriented. Diarrhea and angular stomatitis rapidly improved within a week after the recovery of neurologic symptoms. Complete remission of behavioral symptoms without long-term sequelae was noted.
9.	Filgueiras et al 2011	Case report	Brazil	1	42, Male	Alcoholism	Slowed Thinking	Benign Symmetrical Lipomatosis	Computerized cervical tomography showed multiple lipomas of homogeneous aspect up to the sternal notch, elevated Gamma Glutamyl transferase. Treatment with alcohol abstinence and intravenous B complex supplementation resulted in complete remission of cutaneous symptoms.
10.	Suwalka et al 2018	Case Control	India	200	Arawali group - 32.56 years, 72 male and 28 female Dahod Group - 31.23 years, 78 male and 22 female	Dietary deficiency of Niacin (Maize vs Wheat)	Somatization, Depression and Anxiety	--	Neuropsychological findings revealed significant values in SCL 90 – R depression subscale, anxiety subscale, somatization subscale and global symptom index subscale

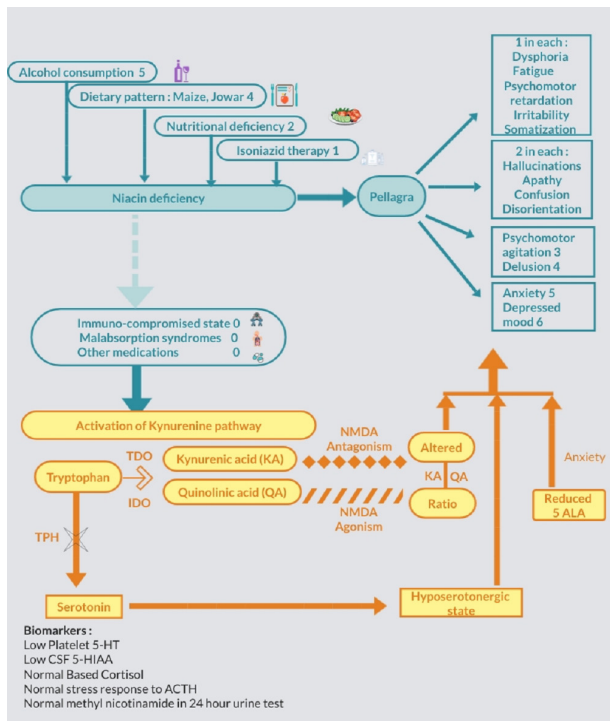
11.	Wang et al 2012	Case Report	China	1	45 years, Male	Dietary deficiency of niacin	Conscious but unable to answer correctly, smiling to self, paranoid hallucination, inappropriate emotions, poor insight, poor concentration	skin around his eyes and forehead -dark brown to black and his hands and forearms covered with flaking skin	A 24-hour urine test found decreased levels of N-methylnicotinamide (<0.5 mg) and a CT of the brain identified abnormalities of the cerebral cortex and diffuse spots around the cerebral ventricles. Treated with high-dose niacin acid, vitamins B and C, and glutamin.
12.	Amanullah et al 2010	Case report	Canada	1	64 year, female	Dietary deficiency	Confused, signs of depression, lack of insight	Beefy, furry and fissured tongue and scaly erythematous lesions on shin bilaterally	Head CT showed frontotemporal atrophy with no hemorrhage and treated with 50 mg niacin daily

or psychotic symptoms except in one report, where improvement in psychotic symptoms was followed by dysphoric mood.<sup>13</sup> None of the studies used a clearly defined duration of clinical depression as per the criteria of the International Classification of Diseases (ICD) or Diagnostic and Statistical Manual of Mental Disorders (DSM).

In terms of dermatological manifestations of pellagra, most studies described the lesions as bilateral symmetrical dermatitis, the details of which are given in Table 1.<sup>1,2,11-15, 17, 19,20</sup>

In regards to treatment, niacin was administered intravenously and orally. The most common oral regimen was 150 mg per day as a part of replacement than supplementation and the dose ranged from 50–500 mg/day. Improvement in the dermatological and gastrointestinal symptoms took a relatively longer time than improvement of psychiatric symptoms to the extent that dramatic improvement in sleep and mood occurred within 24–48 hours after niacin replacement in two reports.<sup>11,14</sup> In addition, a significant role of thiamine, tryptophan, and niacin was observed in early recovery from psychiatric symptoms in almost all the studies. Improvement in psychotic symptoms was noted when olanzapine and haloperidol were augmented with niacin. Except for one report, all the studies reported systemic manifestations of pellagra.<sup>7</sup> In a case of pellagra manifesting as delusional parasitosis, the delusion resolved rapidly after niacin-augmentation therapy and antipsychotic. This supports the role of niacin in treating pellagrous delusional disorder, as reported in similar cases.<sup>13</sup> While growing food faddism in modern days and the increasing prevalence of alcohol use, a high index of suspicion is required in diagnosing NEPM of pellagra and prompt treatment with niacin.<sup>12</sup>

In terms of biological markers of psychiatric manifestations of pellagra, low platelet 5-Hydroxy Tryptamine (5-HT) was observed among cases in two studies,<sup>1,18</sup> and low CSF levels of 5-Hydroxy Indole Acetic Acid (5-HIAA) among pellagrin. Whereas, the basal cortisol and stress response to adrenocorticotrophic hormone (ACTH) administration was comparable among cases and controls.<sup>17</sup> One report documented the reduced levels of N-methyl nicotinamide (<0.5 mg) in a 24 hour urine test.<sup>19</sup> Necropsy



**Figure 2:** Charting of the results of scoping review

TDO- Tryptophan Dioxygenase, IDO-Indolamine Dioxygenase, TPH-Tryptophan Hydroxylase, NMDA- N methyl D Aspartate, KA- Kynurenic acid, QA-Quinolinic Acid, 5ALA- 5 Alpha Levulenic Acid

findings from one case series suggested that 50% of the patients with pellagra had no skin lesions.<sup>20</sup> Table 1 describes the characteristic findings of the included studies. The possible role of kynurenine pathway activation has been reported in the psychiatric manifestations<sup>13</sup> it was observed that the patients with pellagra were all poor, subsisted mainly on maize, and rarely ate fresh meat. Subsequent occurrences have been in the form of epidemic outbreaks, consequent to either introduction to maize as a major food or increased consumption of other niacin-deficient diets like Jowar (*Sorghum vulgare*) and the results are charted in Figure 2.

### Characteristics of Studies on Encephalopathic Psychiatric Manifestations (EPM)

Studies predominantly describing the findings related to delirium, and Wernicke’s encephalopathy in the context of pellagra were termed as encephalopathic psychiatric manifestations (EPM) in this review. These constituted seven case reports, three case series, and two retrospective chart reviews,

including autopsy findings. The majority of them described the neurological manifestations associated with pellagra, such as myoclonus, catatonia, truncal ataxia, rapidly progressive cognitive decline, cerebellar signs, pyramidal signs, oppositional hypertonus, hyperreflexia, apraxia, dysarthria, tremors, nystagmus, extrapyramidal symptoms, spasticity.<sup>7,8,21-31</sup> associated in 13 cases with Marchiafava-Bignami disease and/or Wernicke-Korsakoff disease. The clinical features included confusion and/or clouding of consciousness, marked oppositional hypertonus (‘gegenhalten’ The psychiatric manifestations included apathy, confusion, depressive and anxiety symptoms as described in Table 2. The autopsy findings of suspected pellagrins were laminar cortical necrosis with vacuoles and astrocytosis in the second and third layers of the bilateral frontal cortices, suggesting Morel’s laminar sclerosis.<sup>23</sup> One report mentioned the central chromatolysis in the neurons corresponding to cerebral pellagra, fibrillary astroglia in the tegmentum of the brainstem similar to that of Wernicke’s encephalopathy<sup>31</sup> while only neuronal chromatolysis was reported on one study.<sup>21</sup> associated in 13 cases with Marchiafava-Bignami disease and/or Wernicke-Korsakoff disease. The clinical features included confusion and/or clouding of consciousness, marked oppositional hypertonus (‘gegenhalten’ In terms of neuroimaging findings, the computerized cervical tomography showed multiple lipomas of homogeneous aspect up to the sternal notch<sup>15</sup>. A CT of the brain identified abnormalities of the cerebral cortex and diffuse spots around the cerebral ventricles in one of the reports<sup>19</sup> while in another report, a CT brain showed frontotemporal atrophy<sup>2</sup>.

## DISCUSSION

To the best of our knowledge, this appears to be the first attempt to understand the development of NEPM in pellagra. The symptoms of depression, anxiety, and psychosis may not be noticeable during pellagra because of unawareness of NEPM until the full-blown pellagra manifests. Because alcohol use remains the most common cause of pellagra in the contemporary world, the focus of treatment, therefore, revolves around the management of



**Table: 2** Encephalopathic Psychiatric Manifestations (EPM) of pellagra

Sr. no	Author and year	Type of study	Region	Sample size	Mean age (years)	Probable etiology of pellagra	Psychiatric manifestations including encephalopathy and delirium	Associated Dermatological and Gastrointestinal manifestations	The characteristic finding of the study
	Terada N, Kinoshita K, Taguchi S et al 2015 7	Case report	Japan	1	61	Chronic alcoholism	Disorientation, confusion, Wernicke's encephalopathy	Eye movement impairment, muscle wasting, and a rash over the limbs	In Chronic alcoholics with confusion and erythematous rashes, pellagra is to be considered a differential diagnosis
	Narsimha et al, 2019 27	Retrospective chart review	India	2947	-	Chronic alcoholism and poor nutritional status	Delirium, confusion, Wernicke's encephalopathy, complicated alcohol withdrawal	Dermatitis (100 %), Diarrhea (19%), Underweight (56%)	In 3 year, chart review in ADS patients, pellagra was diagnosed in 1% of cases.
	Chidlovskii E et al, 2012 [25]	Case report	France	1	80	Severe malnutrition and alcohol consumption	Confusion, memory impairment, Wernicke's encephalopathy	No systemic symptoms	Resolution of all symptoms by Niacin supplementation. Malnourished and alcoholic patients showing signs of encephalopathy should receive niacin supplementation
	Oldham MA, Ivkovic A, 2012 6	Case series and review of literature	USA	3	54	Case 1- ADS, HIV and Hep B Case 2 & 3 - ADS	Disorientation, agitation, Delirium in all 3 cases, ataxia in 1 case, and Encephalopathy on EEG in one case	Dermatitis in 2 cases, Diarrhea in only 1 case.	All cases had ADS with a delirious presentation that resolved quickly with nicotinamide and BZD. The Triad of 3D should include- Diarrhea, dermatitis, and Delirium.

Kapas I et al, 2012 <sup>24</sup>	Retrospective chart review	Hungary	5	45	Not described	All cases showed rapid dementia and gait disorder predominantly with cerebellar symptoms, and pyramidal signs described as "Pellagrous encephalopathy"	Not described	In Rapidly progressive dementias with malnutritional status, pellagra should be considered in the differential diagnosis.
Savidou S., 2014 <sup>26</sup>	Case Report	Greece	1	50	Poor, Homeless, poor nutritional status	Confusion, disorientation	A severe case of Pellagra- Dermatitis, scaly elusion on an exposed area. Died due to Hospital-acquired pneumonia	The patient had long-standing severe pellagrous encephalopathy, only partially resolved after niacin supplementation.
Swash M et al, 1972 <sup>23</sup>	Case Series	UK	3	53	Anti-tuberculosis drugs – Ethionamide and Cycloserine	Two patients had apathy, dementia, ataxia, myoclonus	Not described	One must be cautious for signs symptoms of pellagra as rare complications with Anti TB drugs.
Serdau M, et al, 1988 <sup>21</sup>	retrospective postmortem chart review		22	-	ADS	Confusion marked oppositional hypertonus ('gegenhalten') and myoclonus Wernicke's encephalopathy Marchiafava Bignami disease	Dermatitis, Cachexia	Post mortem finding- Neuronal chromatolysis and four had Wernicke's encephalopathy. The most patient died within 1 <sup>st</sup> week of admission

Kobayashi Z, et al, 2010 <sup>23</sup>	Autopsy case report	Japan	1	57	ADS and Gastrectomy	Apraxia of speech and ataxia. Delirium	Diarrhea	Death after 40 days. Autopsy findings were consistent with Wernicke's encephalopathy and pellagra encephalopathy. The laminar cortical necrosis with vacuoles and astrogliosis was found in the second and third layers of the bilateral frontal cortices, suggesting Morel's laminar sclerosis.
Joanna Wallengren and Ingrid Thelin, 2002 <sup>22</sup>	Case report	Sweden	1	40/F	ADS	Ataxia, diplopia, nystagmus, and myoclonus as a part of Wernicke's encephalopathy.	Dermatitis in a sun-exposed area	All symptoms resolved within a few days of multivitamin therapy including Niacin.
Koga M et al, 1978 <sup>31</sup>	Autopsy case report	Japan	1	40	ADS	Delirium, spasticity, hyperreflexia, myoclonus. The patient died after 70 days.	No skin lesion	Autopsy showed centrally chromatolysis in the neurons corresponding to cerebral pellagra or alcoholic pseudo-pellagra, fibrillary astrogliosis in the tegmentum of the brainstem similar to Wernicke encephalopathy
Park K et al, 2015 <sup>5</sup>	Case Report	Japan	1	56	ADS	Disorientation, ataxia, tremors, myoclonus, hyperreflexia, positive Babinski sign, dysuria.	Hyperkeratotic scaly lesion on the face and sun-exposed area	Alcoholic pellagra can develop after the administration of thiamine without niacin because relatively excessive thiamine levels indirectly elevate the demand for niacin.

alcohol use disorder in such patients. The subtle psychiatric manifestations are often presumed as a part of alcohol use disorder which could further go unnoticed due to delayed help-seeking by patients, an emergency presentation, and overlapping symptoms of alcohol withdrawal delirium or encephalopathy<sup>9</sup>. However, subsuming such subacute depressive and anxiety symptoms under the subsyndromal delirium without investigating extrapyramidal symptoms and electroencephalography (EEG) would hardly help the clinician understand the course of the illness. The exact relationship between niacin deficiency and the pathogenesis of depressive or psychotic symptoms is unclear, however many underlying hypotheses, such as neuronal insult through direct cytoplasmic damage, secondary axonal change, and indirect evidence of chromatolysis in the region of the pons, and activation of the immune-inflammatory pathway have been contemplated.<sup>32</sup>

## Summary of Evidence

The NEPM can range from depressive, psychotic, or anxiety symptoms to confusion and disorientation. The psychotic symptoms may not always be associated with encephalopathy or delirium as noted in a few reports<sup>3,11-13</sup> and are difficult to tease out at times from subacute delirium.<sup>9</sup> It is interesting to prospectively follow up the course of illness in suspected patients with pellagra without dermatological manifestations and treat them with niacin up to 150–300 mg/day while monitoring the urinary metabolites of serotonin and niacin. Mention of depression, neurasthenia, irritability, and apathy reflects the classical endogenous symptoms of depression recorded during the evolution of pellagra in reported cases<sup>20</sup> and could help us in improving the understanding of a few subtypes of depression. Further rapid response and rapid resolution of psychiatric symptoms with niacin replacement is a characteristically unique finding in the context of pellagra.<sup>3,11-14</sup> Routine supplementation with niacin among alcohol use disorders is an area worth exploring in future prospective studies.

An immune-inflammatory biochemical pathway underlying the psychiatric manifestations of pellagra is partly related to the conversion of tryptophan to

niacin and requires a brief discussion here<sup>33,14,34,35</sup>. Niacin deficiency can activate the liver enzymes - tryptophan dioxygenase (TDO) and indolamine dioxygenase (IDO), causing tryptophan to undergo oxidation via the kynurenine pathway. As the brain cannot synthesize tryptophan, its unavailability predisposes to the development of a hypo-serotonergic state that possibly manifests as lethargy, dysphoria, sadness, and anhedonia.<sup>36</sup> It is also true that TDO, a rate-limiting enzyme of kynurenine synthesis, is upregulated by glucocorticoids under a pro-inflammatory state in pellagra. In such circumstances, the tryptophan is metabolized into kynurenic acid (KA), and quinolinic acid (QA) which acts as an N-methyl D-aspartate (NMDA) antagonist, and agonist, respectively.<sup>37</sup> Lower KA/QA ratio initially predisposes hyper-glutamatergic state due to reduced bioavailability of tryptophan and worsening of depressive symptoms that are further amplified by reduced energy utilization in the absence of niacin, and its end-product nicotinamide adenine dinucleotide phosphate (NADPH).<sup>38</sup> Chronic deficiency of tryptophan worsens the pro-inflammatory state. The body tries to establish homeostasis through activating anti-inflammatory cytokines by reversing the KA/QA ratio that develops a hypo-glutamatergic state and psychosis-like symptoms in the course of Pellagra.<sup>39</sup> Since most cases of pellagra are induced by regular alcohol consumption, its withdrawal leads to glutamatergic toxicity associated with gamma amino butyric acid (GABA) scarcity.<sup>40</sup> Such a rapidly fluctuating shift in KA/QA ratio could create a state of disorientation and confusion that tends to respond quickly to supplementation with niacin, and small doses of GABA facilitators such as benzodiazepines. The reversal of the hepatic kynurenine pathway by the end-product NADPH inhibition also results in the rapid resolution of psychiatric symptoms. One more interesting hypothesis is intermediate haem precursor 5- Amino Levulenic Acid (5-ALA) which acts as a powerful inhibitor of GABA, leading to worsening of the hypo-serotonergic state that can produce non-specific anxiety symptoms in pellagra apart from photosensitivity of pellagrous dermatitis.<sup>32</sup> Another potential contributor to serotonin deficiency in this cascade is a possible impaired decarboxylation of the immediate serotonin pre-

cursor 5-hydroxytryptophan by the pyridoxal 50-phosphate-dependent aromatic L-amino acid decarboxylase (ALAAD), whose activity is impaired in (functional) vitamin B6 deficiency and explains the supplemental role of vitamin B6 in the treatment.<sup>32</sup>

Although current evidence is mixed regarding niacin replacement in cases of depression and psychosis<sup>41-43</sup> the biochemical changes postulated for pellagra could help us to unravel the neurobiology of a subset of independent psychiatric disorders.<sup>2</sup> Recently in a case of Crohn's disease, abnormal level of 5-OH-indoleacetic acid in a 24-hour urine test, and metabolites of 1-methyl nicotinamide, and the ratio of levels of 1-methyl-2-pyridone-5-carboxamide to blood creatinine are proposed as biomarkers for pellagra<sup>44</sup>. Niacin has also been implicated in non-pellagrous depressive disorders in recent studies; therefore, these biomarkers also provide a ray of hope to assist in diagnosis of psychiatric disorders. Future studies should look at the consistency of depressive and psychotic symptoms as discussed in this review and the role of niacin replacement in their reversal.

## Limitations

The review is focused on selected psychiatric manifestations i.e., depression, anxiety, and psychosis during pellagra. There is a paucity of data and also it is difficult to distinguish anxiety, depressive and psychotic symptoms from a broad gamut of encephalopathy, therefore, the overlapping symptoms reported in a few case reports could be the limitation of this review.

## CONCLUSION

It is crucial to timely recognize the importance of differentiating encephalopathic and non encephalopathic psychiatric manifestations of pellagra. While encephalopathic presentations are acute, the non encephalopathic presentations could be subacute to chronic. The indirect involvement of the kynurenine system and niacin supplementation's effect during evolution of subacute psychiatric symptoms requires further research. Therefore, the commonly occurring depressive, anxiety, and psychotic symptoms in an

individual with chronic alcohol consumption should be assessed, and investigated carefully for possible niacin deficiency. The possible role of niacin supplementation in subacute presentations of NEPM in pellagra cases could potentially halt its progression to encephalopathy by correcting the underlying biochemical imbalance. In future, this association may be supported by measuring 5-hydroxy tryptamine (5-HT), 5-hydroxy indole acetic acid (5-HIAA), cortisol, and immune-inflammatory markers in serum, cerebrospinal fluid, and platelets. Rapid identification of psychiatric symptoms supported by investigations on the immune markers, and treatment with nicotinic acid should also be attempted independently in a subgroup of psychiatric disorders where the shared immune-inflammatory hypothesis is contemplated.

## Financial disclosure

None.

## Conflict of Interest

No conflict of interest.

## REFERENCES

1. Krishnaswamy K, Murthy PSVR. Mental changes and platelet serotonin in pellagrins. *Clin Chim Acta*. 1970;27(2):301-304. doi:10.1016/0009-8981(70)90348-7
2. Amanullah S, Seeber C. Niacin deficiency resulting in neuropsychiatry symptoms: a case study and review of literature. *Clin Neuropsychiatry*. Published online 1st February, 2010:10-15. Accessed 9th February, 2022. <https://go.gale.com/ps/i.do?p=HRCA&sw=w&issn=17244935&v=2.1&it=r&id=GALE%7CA228121874&sid=google-scholar&linkaccess=fulltext>
3. López M, Olivares JM, Berrios GE. Pellagra encephalopathy in the context of alcoholism: Review and case report. *Alcohol Alcohol*. 2014;49(1):38-41. doi:10.1093/alcalc/agt070
4. Sharma B, Sannegowda RB, Jain R, Dubey P, Prakash S. A rare case of alcoholic pellagra encephalopathy with startle myoclonus and marked response to niacin therapy: time for a new dictum? *BMJ Case Rep*. Published online 2013. doi:10.1136/bcr-2013-008906
5. Park SH, Na DL, Lee JH, et al. Alcoholic pellagra encephalopathy combined with Wernicke disease. *J Korean Med Sci*. 1991;6(1):87-93. doi:10.3346/jkms.1991.6.1.87
6. Park K, Oeda T, Sawada H. A case of alcoholic pellagra encephalopathy presenting with spinal myoclonus. *Neurol Clin Pract*. 2015;5(6):472-474. doi:10.1212/CPJ.0000000000000165
7. Oldham MA, Ivkovic A. Pellagrous encephalopathy



- presenting as alcohol withdrawal delirium: A case series and literature review. *Addict Sci Clin Pract*. Published online 2012. doi:10.1186/1940-0640-7-12
8. Terada N, Kinoshita K, Taguchi S, Tokuda Y. Wernicke encephalopathy and pellagra in an alcoholic and malnourished patient. 2015;2015:bcr2015209412. Accessed 8th February, 2022. <https://casereports.bmj.com/content/2015/bcr-2015-209412>
  9. Slooter AJC, Otte WM, Devlin JW, et al. Updated nomenclature of delirium and acute encephalopathy: statement of ten Societies. *Intensive Care Med* 2020 465. 2020;46(5):1020-1022. doi:10.1007/S00134-019-05907-4
  10. Tricco AC, Lillie E, Zarin W, et al. PRISMA extension for scoping reviews (PRISMA-ScR): Checklist and explanation. *Ann Intern Med*. 2018;169(7):467-473. doi:10.7326/M18-0850
  11. Pitsavas S, Andreou C, Bascialla F, Bozikas VP, Karavatos A. Pellagra encephalopathy following B-complex vitamin treatment without niacin. *Int J Psychiatry Med*. 2004;34(1):91-95. doi:10.2190/29XV-1GG1-U17K-RGJH
  12. Delgado-Sanchez L, Godkar D, Niranjana S. Pellagra: Rekindling of an old flame. *Am J Ther*. 2008;15(2):173-175. doi:10.1097/MJT.0b013e31815ae309
  13. Prakash R, Gandotra S, Singh LK, Das B, Lakra A. Rapid resolution of delusional parasitosis in pellagra with niacin augmentation therapy. *Gen Hosp Psychiatry*. 2008;30(6):581-584. doi:10.1016/j.genhosppsych.2008.04.011
  14. Luthe SK, Sato R. Alcoholic Pellagra as a Cause of Altered Mental Status in the Emergency Department. *J Emerg Med*. 2017;53(4):554-557. doi:10.1016/j.jemermed.2017.05.008
  15. Filgueiras F de M, Stolarczuk D de A, Gripp AC, Succi ICB. Lipomatose simétrica benigna e pelagra, associadas ao alcoolismo. *An Bras Dermatol*. 2011;86(6):1189-1192. doi:10.1590/S0365-05962011000600021
  16. Suwalka BM, Rohatagi S. International Journal of Medical Science and Education An official Publication of Association for Scientific and Medical Education (ASME) PELLAGRA ASSOCIATED WITH PSYCHIATRIC ILLNESSES IN VAGHAD AND ARAVALI HILL AREAS NEAR UDAIPUR. *Int.j.med.sci.educ*. 5(1):112-116. Accessed 8th February, 2022. [www.ijmse.com](http://www.ijmse.com)
  17. Krishnaswamy K. Plasma "cortisol" levels in pellagrins. *Clin Chim Acta*. 1971;34(3):415-418. doi:10.1016/0009-8981(71)90094-5
  18. Raghuram TC, Krishnaswamy K. Serotonin Metabolism in Pellagra. *Arch Neurol*. 1975;32(10):708-710. doi:10.1001/archneur.1975.00490520078015
  19. Wang W, Liang B. Case report of mental disorder induced by niacin deficiency. *Shanghai Arch psychiatry*. 2012;24(6):352-354. doi:10.3969/J.ISSN.1002-0829.2012.06.008
  20. Ishii N, Nishihara Y. Pellagra encephalopathy among tuberculous patients: Its relation to isoniazid therapy. *J Neurol Neurosurg Psychiatry*. 1985;48(7):628-634. doi:10.1136/jnnp.48.7.628
  21. Serdaru M, Hausser-hauw C, Laplane D, et al. THE CLINICAL SPECTRUM OF ALCOHOLIC PELLAGRA ENCEPHALOPATHY: A RETROSPECTIVE ANALYSIS OF 22 CASES STUDIED PATHOLOGICALLY. *Brain*. 1988;111(4):829-842. doi:10.1093/BRAIN/111.4.829
  22. Wallengren J, Thelin I. Pellagra-like skin lesions associated with Wernicke's encephalopathy in a heavy wine drinker [11]. *Acta Derm Venereol*. 2002;82(2):152-154. doi:10.1080/00015550252948301/
  23. Kobayashi Z, Tsuchiya K, Takahashi M, et al. Morel's laminar sclerosis showing apraxia of speech: Distribution of cortical lesions in an autopsy case. *Neuropathology*. 2010;30(1):76-83. doi:10.1111/J.1440-1789.2009.01039.X
  24. Kapas I, Majtenyi K, Török K, Keller E, Voigtländer T, Kovacs GG. Pellagra encephalopathy as a differential diagnosis for Creutzfeldt-Jakob disease. *Metab Brain Dis* 2012 272. 2012;27(2):231-235. doi:10.1007/S11011-012-9308-8
  25. Chidlovskii E, Tahar A, Deschasse G, Couturier P. Encéphalopathie de Gayet Wernicke associée à une encéphalopathie pellagrique : complication rare et inhabituelle chez une femme âgée hospitalisée pour pneumopathie d'inhalation. *La Rev Médecine Interne*. 2012;33(8):453-456. doi:10.1016/J.REVMED.2012.05.010
  26. Savvidou S. Pellagra: A Non-Eradicated Old Disease. *Clin Pract* 2014, Vol 4, Page 637. 2014;4(1):637. doi:10.4081/CP.2014.637
  27. Narasimha VL, Ganesh S, Reddy S, et al. Pellagra and Alcohol Dependence Syndrome: Findings From a Tertiary Care Addiction Treatment Centre in India. *Alcohol Alcohol*. 2019;54(2):148-151. doi:10.1093/ALCALC/AGZ004
  28. Acute encephalopathy due to coexistent nicotinic acid and thiamine deficiency - PubMed. Accessed 19th April, 2022. <https://pubmed.ncbi.nlm.nih.gov/8117565/>
  29. Swash M, Roberts AH, Murnaghan DJ. Reversible pellagra-like encephalopathy with ethionamide and cycloserine. *Tubercle*. 1972;53(2):132-136. doi:10.1016/0041-3879(72)90030-X
  30. A suspected case of alcoholic pellagra encephalopathy with marked response to niacin showing myoclonus and ataxia as chief complaints] - PubMed. Accessed 19th April, 2022. <https://pubmed.ncbi.nlm.nih.gov/16519110/>
  31. Koga M, Shimono M, Tateishi J, Ikuta F. Chronic Alcoholism: Report of an Autopsy Case and Comparison With Pseudoulegyric Type of Hepatocerebral Degeneration. *Psychiatry Clin Neurosci*. 1978;32(1):141-148. doi:10.1111/J.1440-1819.1978.TB02788.X
  32. Badawy AAB. Pellagra and alcoholism: A biochemical perspective. *Alcohol Alcohol*. 2014;49(3):238-250. doi:10.1093/alcalc/agu010
  33. Kertesz SG. Pellagra in 2 homeless men. *Mayo Clin Proc*. 2001;76(3):315-318. doi:10.4065/76.3.315
  34. Li R, Yu K, Wang Q, Wang L, Mao J, Qian J. Pellagra Secondary to Medication and Alcoholism. *Nutr Clin Pract*. 2016;31(6):785-789. doi:10.1177/0884533616660991
  35. Lu JY, Yu CL, Wu MZ. Pellagra in an immunocompe-

- tent patient with cytomegalovirus colitis [14]. *Am J Gastroenterol.* 2001;96(3):932-934. doi:10.1016/S0002-9270(00)02452-7
36. Dean J, Keshavan M. The neurobiology of depression: An integrated view. *Asian J Psychiatr.* 2017;27:101-111. doi:10.1016/J.AJP.2017.01.025
37. Steiner J, Bogerts B, Sarnyai Z, et al. Bridging the gap between the immune and glutamate hypotheses of schizophrenia and major depression: Potential role of glial NMDA receptor modulators and impaired blood-brain barrier integrity. *World J Biol Psychiatry.* Published online 2012. doi:10.3109/15622975.2011.583941
38. Bay-Richter C, Linderholm KR, Lim CK, et al. A role for inflammatory metabolites as modulators of the glutamate N-methyl-d-aspartate receptor in depression and suicidality. *Brain Behav Immun.* Published online 2015. doi:10.1016/j.bbi.2014.07.012
39. Müller N, Schwarz MJ. The immune-mediated alteration of serotonin and glutamate: Towards an integrated view of depression. *Mol Psychiatry.* Published online 2007. doi:10.1038/sj.mp.4002006
40. Brousse G, Arnaud B, Vorspan F, et al. alteration of glutamate/GABA balance during acute alcohol withdrawal in emergency department: A prospective analysis. *Alcohol Alcohol.* Published online 2012. doi:10.1093/alcalc/ags078
41. Gabrynowicz JW, Dumbrell M. A clinical trial of leptazole with nicotinic acid in the management of psycho-geriatric patients. *Med J Aust.* 1968;1(19):799-802. doi:10.5694/j.1326-5377.1968.tb28911.x
42. Chouinard G, Young SN, Annable L, Sourkes TL. TRYPTOPHAN-NICOTINAMIDE COMBINATION IN DEPRESSION. *Lancet.* 1977;309(8005):249. doi:10.1016/S0140-6736(77)91036-4
43. Dickerson JWT, Wiryanti\* J. Pellagra and mental disturbance. *Proc Nutr Soc.* 1978;37(2):167-171. doi:10.1079/PNS19780021
44. Hui S, Heng L, Shaodong W, Fangyu W, Zhenkai W. Pellagra affecting a patient with Crohn's disease. *An Bras Dermatol.* 2017;92(6):879. doi:10.1590/ABD1806-4841.20174461